


# Radial ray\ thumb anomalies

Gráinne Bourke  
Leeds Teaching Hospitals



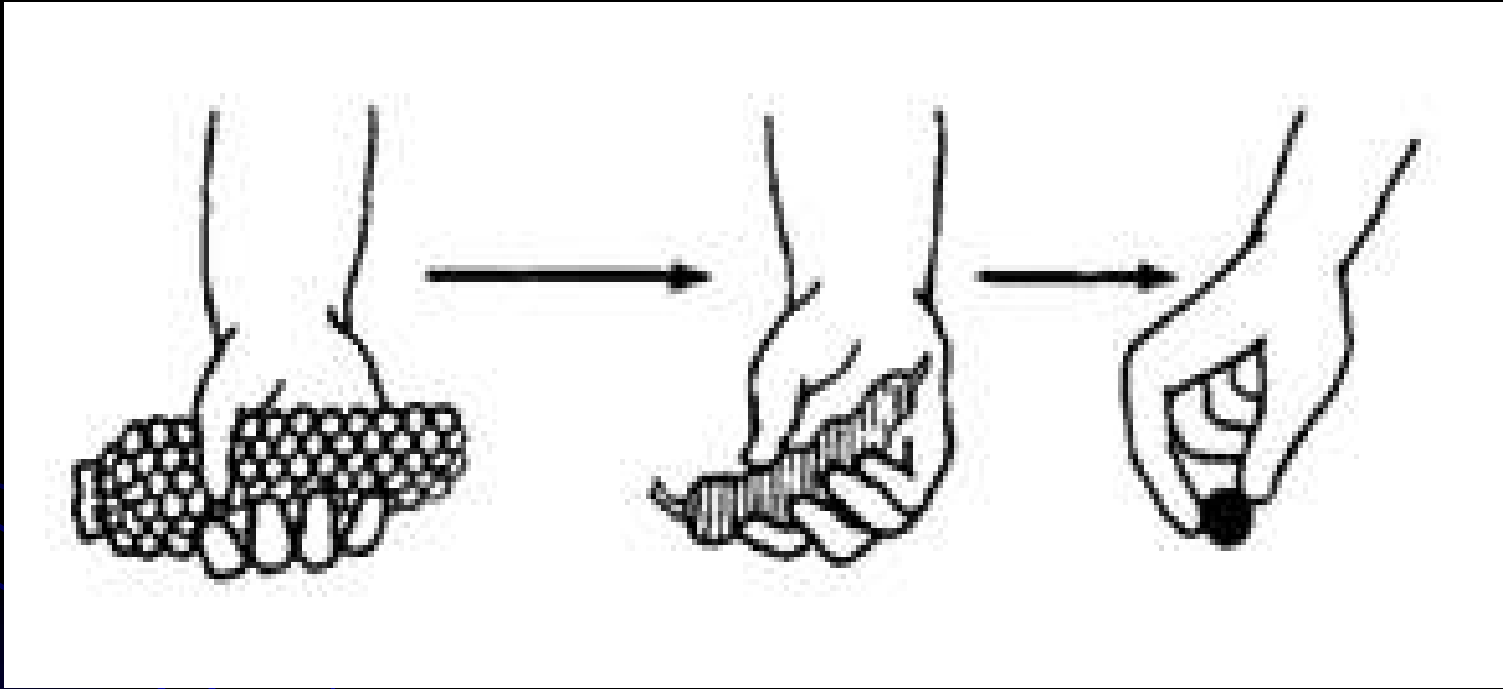
# Children's hand clinic

- Plastic surgeons
- Physiotherapy
- Psychology
- Play therapists
- Nurses
  - Ward
  - Dressings clinic
- Theatre staff
- Anaesthetists



# Swanson - ASHS

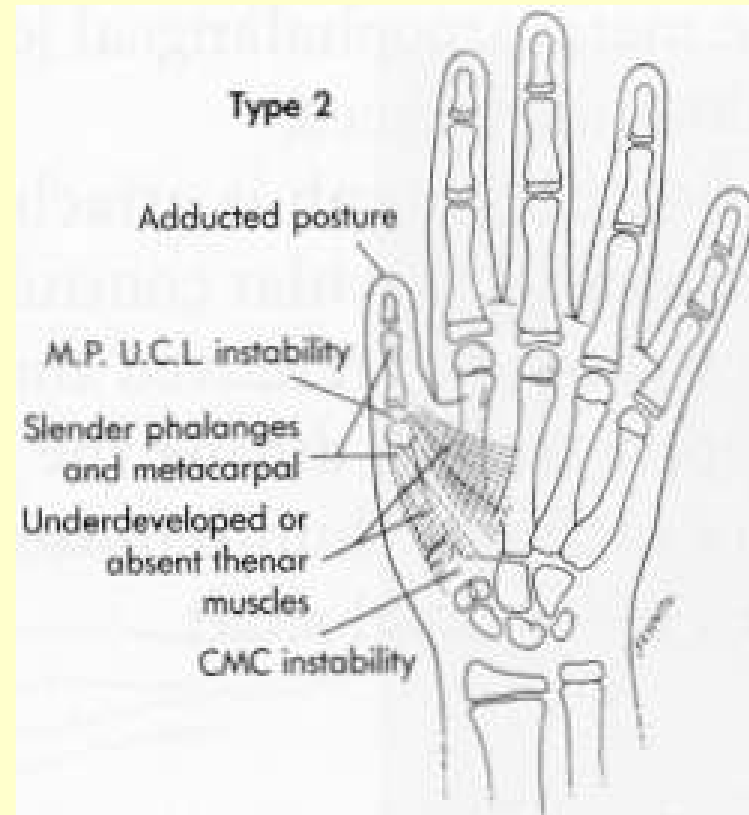
- Failure of formation
- Failure of differentiation
- Duplication
- Overgrowth
- Undergrowth
- Constriction ring syndromes
- Generalised skeletal abnormalities



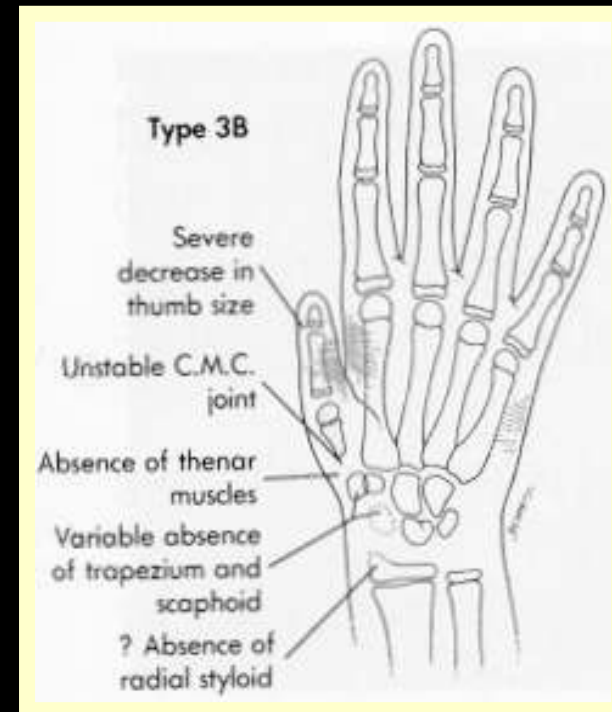
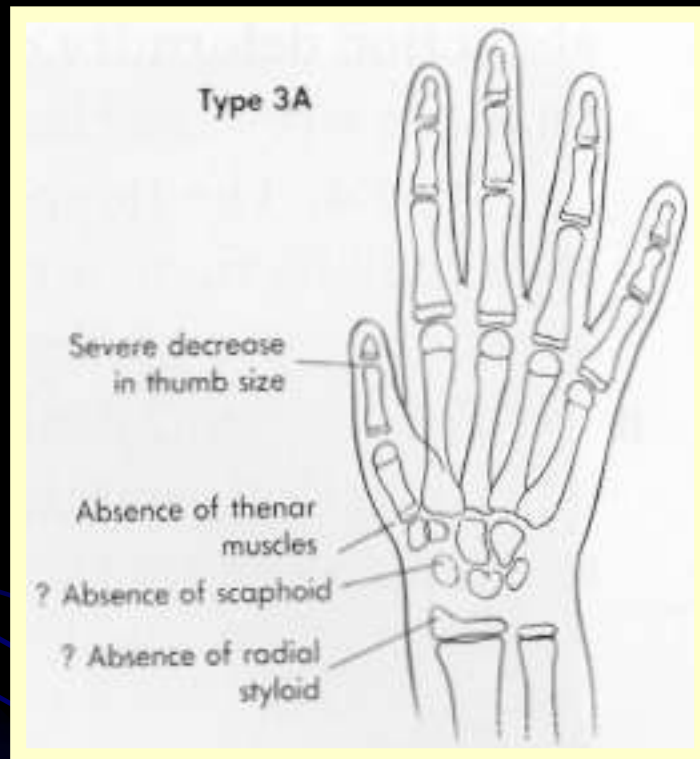
# Blauth Classification

- Type 1
  - Small thumb
- Type 2
  - Hypoplastic thenar muscles
  - Adducted first web space
  - Laxity of the UCL
  - Normal skeleton
- Type 3
  - Skeletal hypoplasia
  - Intrinsic hypoplastic
  - Rudimentary extrinsics
- Type 4
  - Pouce flottant
- Type 5
  - Total absence

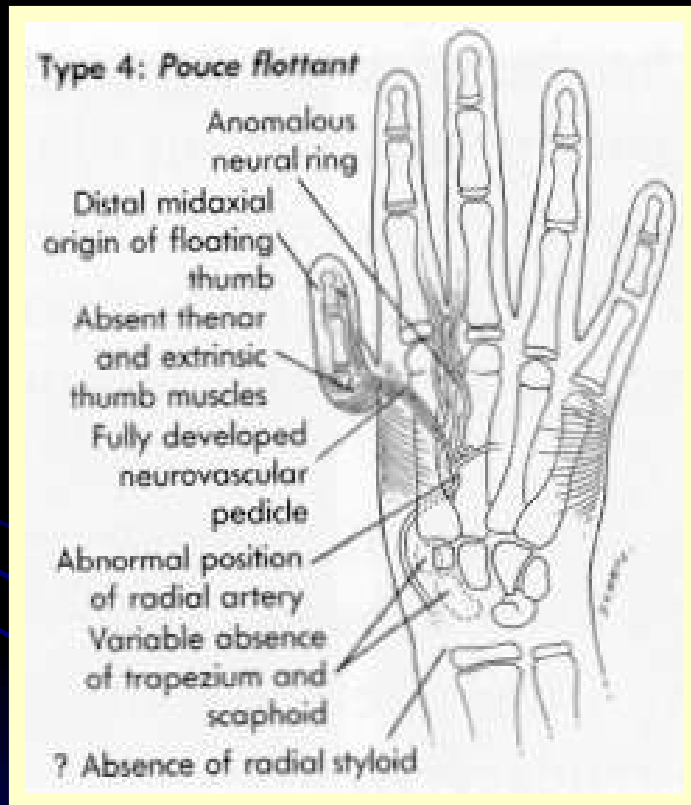
# Type 2



# Typ3 3a\3b



# Type 4





# Type 5

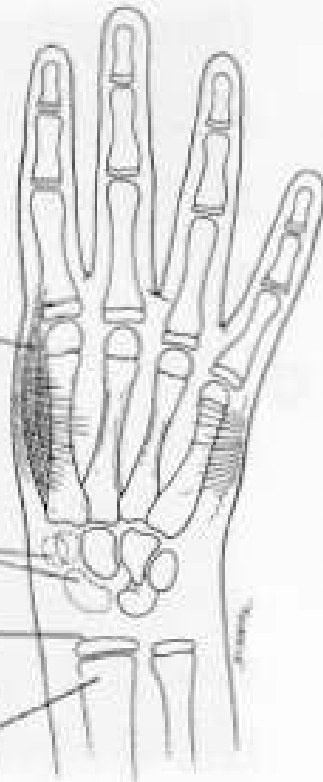## Type 5: Aplasia

Absent first D1  
(abductor indicis)  
in 50% of patients

Absent radial  
carpal bones

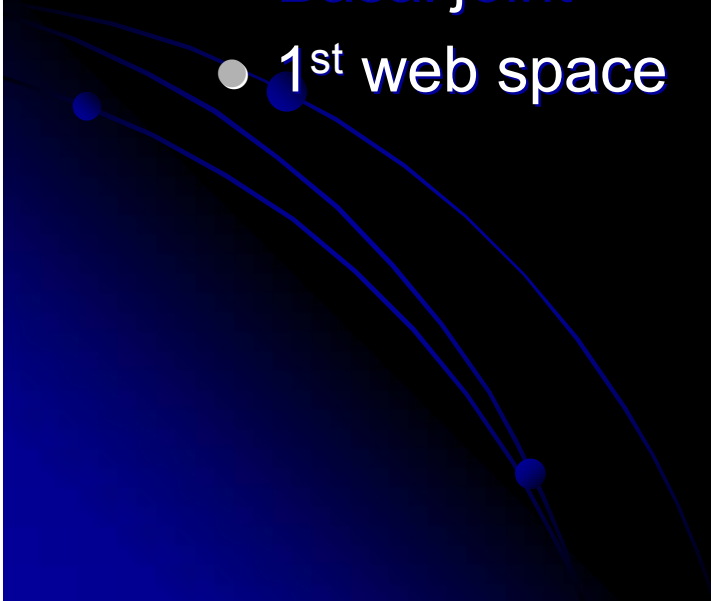
Absent distal  
styloid

Hypoplasia of  
distal radius




# Treatment

- Length
- Alignment
- Stability
- Movement
  - Basal joint
  - 1<sup>st</sup> web space



# POLLICIZATION



# Longitudinal radial deficiency

- **Spectrum of deficiencies**

- **Radius**

- **Carpus**

- **Thumb**

# TREATMENT

## ● Nonoperative:

- Mild anomaly, good function
- Severe associated anomalies or retardation
- Older patients with good adaptation
- Limited elbow flexion (90°)
- Severe soft tissue contracture (N/V)

# TREATMENT

- **Manipulation and Casting/Splinting**
  - **Alone for very mild deficiency**
  - **As adjunct to surgical therapy**
  - **Start in neonatal period**
  - **Hand/wrist/elbow**

## ● Surgical

- Stabilize carpus in corrected position

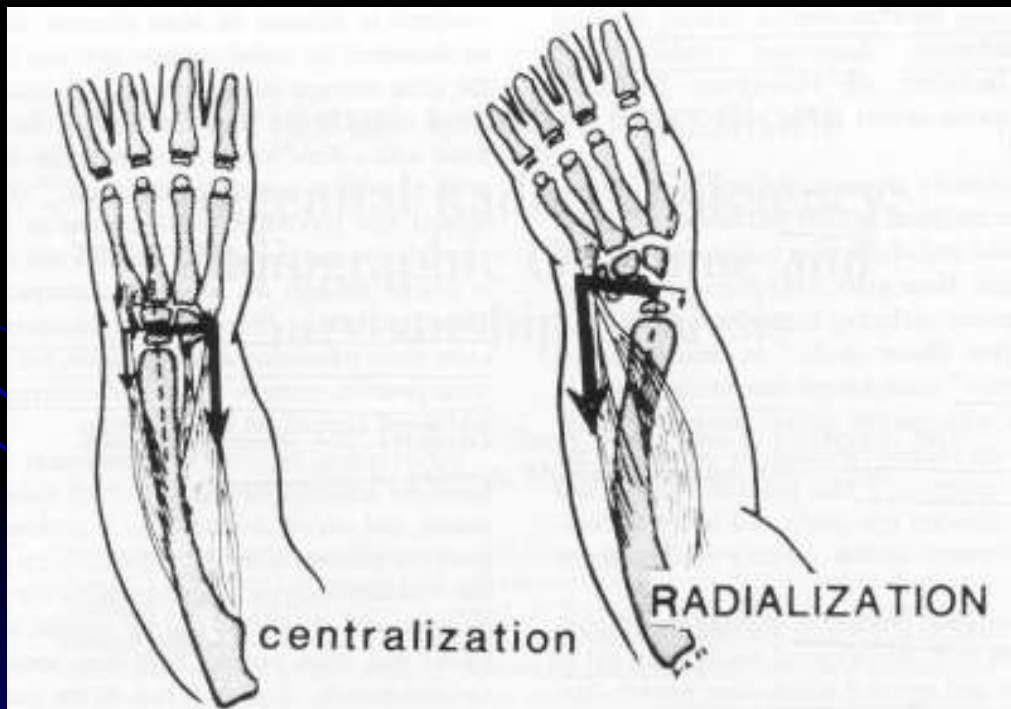
- *Effectively* lengthen upper extremity

- Allow thumb reconstruction

- Aesthetic considerations

# TREATMENT

## ● Surgical: Centralization



Buck-Gramcko, D. *JHS*  
10A: 964, 1985.



# TREATMENT

- **Surgical: Adjunctive Techniques**
  - **Distraction osteogenesis**
  - **Ulna osteotomy**
  - **Tendon transpositions**

# Radial polydactyly


- Unilateral
- Hypoplastic parts
- Anatomy variable
- Wassel classification
  - radiological



- **Wassel classification**

Ezaki M: *Radial Polydactyly*. Hand Clin 6:577, 1990.

# Triphalangeal thumb



# Treatment

- Length
- Alignment
- Stability
- Movement
  - Basal joint
  - 1<sup>st</sup> web space

